

Original Research Article

<https://doi.org/10.20546/ijcmas.2017.607.069>

Malignant Mixed Mammary Tumor in a German Shepherd Middle Age Bitch

G.B. Kumbhar*

Department of Microbiology Collage of Veterinary and Animal Science,
Udgir 413517(MS), Latur, India

**Corresponding author*

ABSTRACT

Keywords

Malignant mixed
mammary tumor,
German shepherd.

Article Info

Accepted:
04 June 2017
Available Online:
10 July 2017

Mammary tumors are the most common tumors in bitches after skin tumor. The risk of mammary tumor is correlated with the age of spaying. Therefore, clinical and histopathological findings and surgical management of an unusual case of benign malignant mixed mammary tumor in German shepherd middle aged bitch is reported.

Introduction

History and clinical examination

A nine year old bitch was presented to Teaching Veterinary Clinical Service Complex, Udgir with the history of abnormally pedunculated, slight moving, progressively growing, large, hard, ossified and cystic subcutaneous growth at the right caudal abdomen in the inguinal mammary gland. All clinical parameters i.e. heart rate, respiration rate, pulse rate and temperature were normal. The condition was clinically diagnosed as tumour of mammary gland and planned for the surgical intervention.

Treatment and discussion

The animal was given general anesthesia by thiopental sodium @ 20 mg/kg BW with

atropine sulphate @ 0.01mg/kg BW. Premedication (Hall and Cleorke, 1991). After development of surgical anesthesia two elliptical incisions were made just above and below the tumour mass and it was removed completely. The blood vessels were legated with catgut No.1 and subcutical tissue was sutured with catgut No.1 by continuous lockstitch sutures. The skin was sutured with medium monofilament nylon with simple interrupted pattern.

Post operatively Inj. ceftriaxone 500 mg IM, Inj. Meloxicam 2 ml IM and DNS 250ml daily was given for five days. Daily dressing with Savlon and Himax ointment was prefferd for nine days. Injection Ceftriaxone acted as

antibiotic, meloxicam as an antinflammatory, DNS as a source of energy and daily dressing with Savlon and Himax ointment helped for hastening the healing. Sutures were removed on 9th post-operative day. Animal recovered uneventfully.

Microbiological isolation and identification

Sterilized swab (Himedia) was introduced into material present in individual cyst, in a strict aseptic manner. Collected material was cultured in nutrient broth and isolated organisms from broth were streaked on Nutrient agar and Mac Conkeys agar. The organisms present in broth were also subjected to direct microscopic examination using Gram staining method. Further, the bacterial isolates were subjected to biochemical test for confirmatory identification of bacteria.

Also, antibiotic sensitivity test was carried out on Mullar Hinton agar. Microbiological isolation and identification was carried out as

per standard method described by Cruickshank *et al.*, 1975. Microscopic examination revealed small, gram positive rods under high power microscope. The colonies of organisms on nutrient agar were large translucent, grayish white, which when exposed to light, showed fluorescent appearance and also putrefied smell was evident. Colonies on Mac Conkeys agar were large and non-lactose fermenting. Bacteria showed motility when observed under microscope. Bacteria were identified as *Pseudomonas* on the basis of biochemical test such as indole positive, MR and VP, negative and citrate positive.

Antibiotic sensitivity test revealed that the organisms were sensitive for Ciprofloxacin, Gentamicin, and Neomycin, whereas resistance for Amoxicillin and intermediate for Chloramphenicol. The bacterial isolation and sensitivity test helped in further treatment of the bitch.

Fig.1 Proliferated acinar and epithelial cells along with fibrinous connective tissue in a section

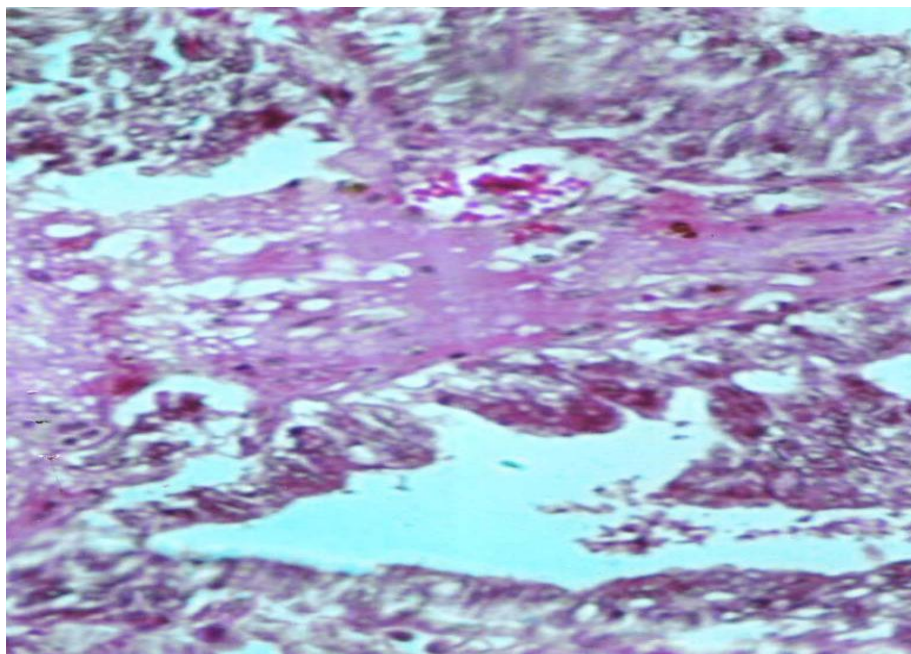
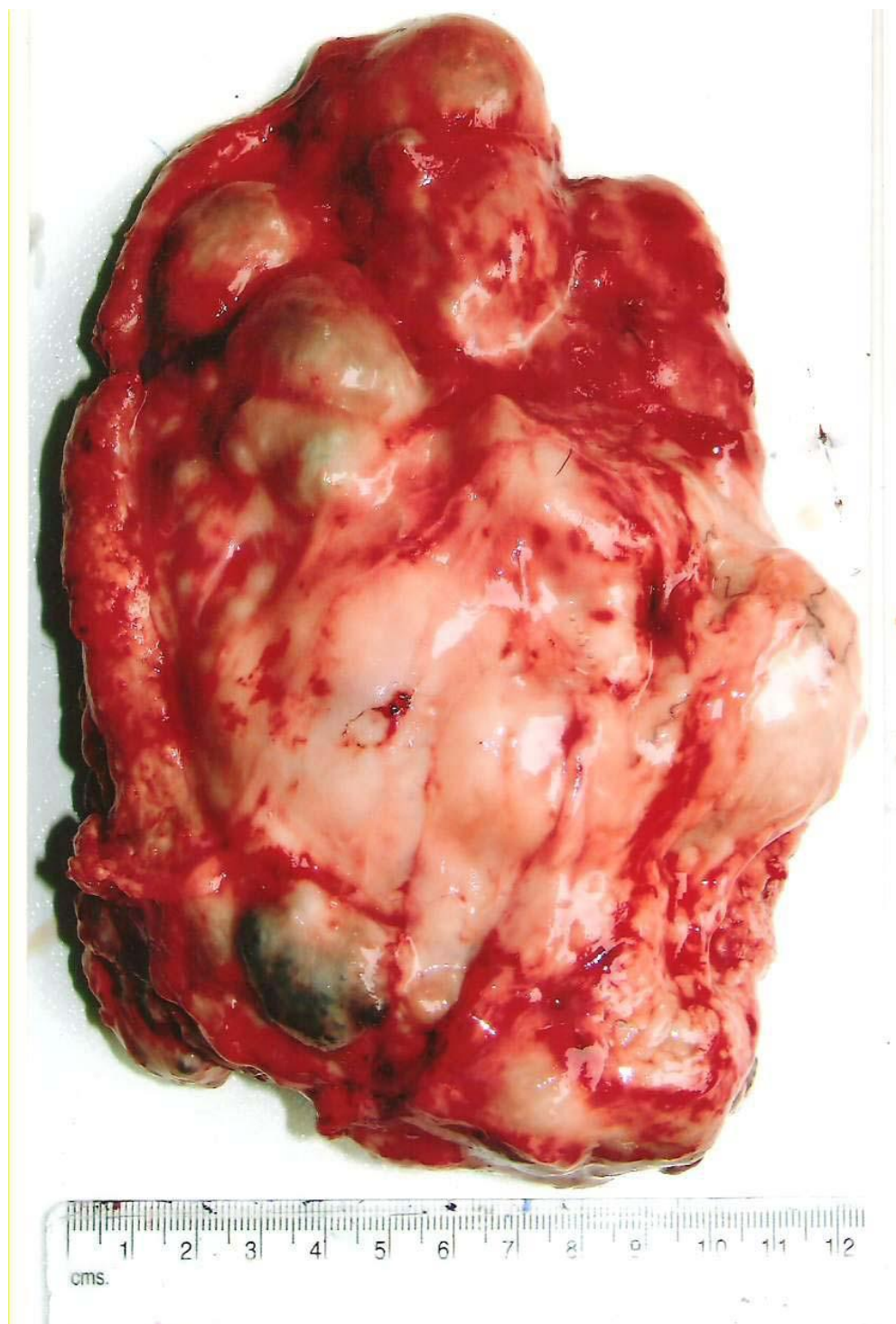


Fig.2 An abnormal growth on ventral, middle, posterior abdomen on mammary gland in bitch

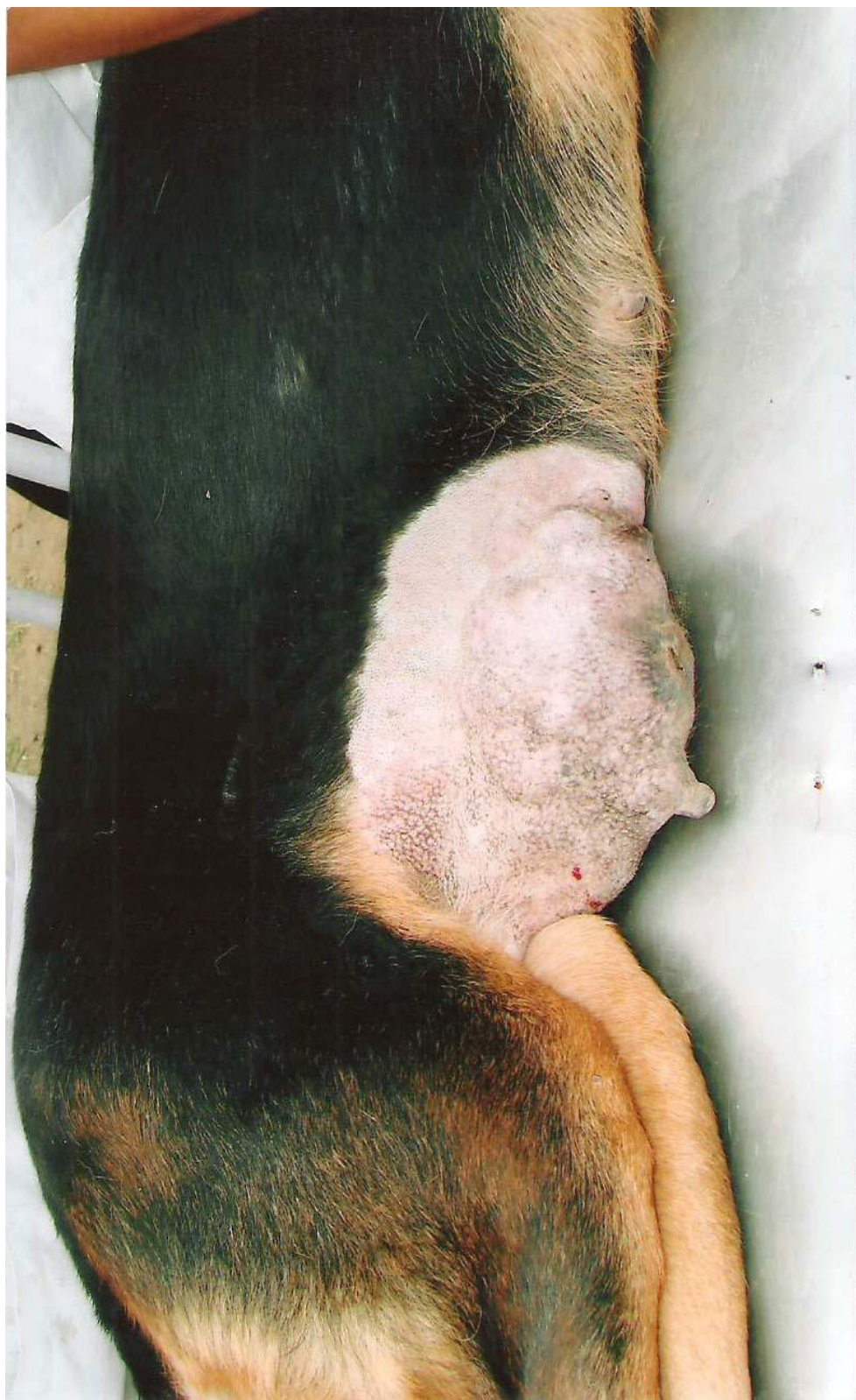

Fig.3 Pendulated masses in a tumor mass after removal



Pathological findings

The macroscopic examination revealed that the swelling was abnormal, pendulated,

slightly moving 16x12 cm sized, and oval to square shaped and gray to pink colored growth which was present from two months, on ventral middle posterior abdomen covering

right side of mammary gland (Figs. 1 and 2). On excision, multiple cystic whitish to gray colored abnormal growths were observed. The multiple cysts were thin walled containing thin watery greenish fluid having foetid odour. The weight of growth was 488gms.

The histopathological examination of excised tissue showed proliferation of both acinar and epithelial cells and fibrous connective tissue (Fig. 1). The acinar cells appear round or oval, hypochromic with plenty of mitotic figures. The separate cluster of proliferating cells were also seen scattered, in the inner acinar tissue hemorrhages and necrosis were also observed and it was identified as mixed tumor containing mixture of epithelial (adenoma) myoepithelial and mesenchymal cells. The mesenchymal cells were metaplastic into cartilaginous tissue. The findings of present study go well with earlier reports of Molten (1978) and Arican *et al.*, (2007).

The case of malignant mixed mammary tumor in German shepherd middle aged bitch has been reported which was diagnosed on histopathological examination and corrected surgically.

References

- Cruickshank, R., Duguid, J.P., Marmion, B.P. and Swain, R.H.A (1975): Medical Microbiology 12th Edn. Vol.2nd Churchill Livingstone, Edinburgh, London.
- Hall, L.W. and Cleorke, K.W (1991): Veterinary Anesthesia, 9th Edn. English Language Book Society and Baillere Tindal, London, pp: 300.
- John Abraham, Spancer Franis. (2007): Indian Vet. J., 84:967.
- Vegad, J.L. (1995): In Text Book of Veterinary General Pathology 1st Edn, Vikas Publishing House, New Delhi, p.276.

How to cite this article:

Kumbhar, G.B. 2017. Malignant Mixed Mammary Tumor in a German Shepherd Middle Age Bitch. *Int.J.Curr.Microbiol.App.Sci*. 6(7): 572-576.
doi: <https://doi.org/10.20546/ijcmas.2017.607.069>